

# Advantages of Using the VACORA™ Breast Biopsy System – A Pathologist’s Perspective

**BRIAN SHIRO, MD<sup>1</sup>**

## INTRODUCTION

The impact of breast carcinoma on our society is huge. The incidence in the United States appears to be increasing – from 105 cases per 100,000 individuals in 1975 to 135 per 100,000 in 2000. There were 216,000 new cases of invasive breast carcinoma and 40,200 deaths due to breast cancer in 2003. Women across the country are scared, and more of them every day are turning to physicians for help.

The best hope for long-term survival of breast carcinoma is an accurate diagnosis in the earliest detectable stage. This fact makes it imperative that all physicians who diagnose and treat patients with breast lesions be in close communication with one another. Any technological advance that improves the ability to more rapidly and accurately diagnose breast lesions is important. The VACORA™ Breast Biopsy System (Bard Biopsy Systems, Tempe, AZ, USA), used in radiologically directed breast needle core biopsies, is one such advance. It efficiently and cost effectively provides a larger, more representative specimen. Before specifically examining these benefits, an abbreviated review of breast core needle biopsy is in order.

## OVERVIEW

Core needle biopsy (CNB) of the breast is used to reduce the incidence of open surgical biopsies. Most pathologists prefer CNB to fine needle aspiration. First, in many locales, the incidence of unsatisfactory fine needle aspiration (FNA) is unacceptably high. Second, FNA of the breast requires a level of expertise in cytopathology unavailable in some areas. General pathologists more confidently interpret the results of a core of tissue. Third, it is impossible to distinguish in situ carcinoma from invasive carcinoma on the basis of the FNA specimen. This distinction is important because node sampling can be done at the same time as an excisional biopsy or mastectomy or pre-operative chemotherapy can be administered if it is known that the patient has invasive carcinoma. Finally, CNB allows ancillary testing such as immunohistochemical studies to be performed. This is impractical, if not impossible, with FNA alone. What about the advantages of CNB over open biopsy? The minimal invasiveness, reduction in clinically significant complications and reduced cost of CNB are major benefits. CNB is also less time consuming.

In addition, CNB usually leaves no scar or persistent mammographic changes (“pseudolesions”) that might hinder future radiographic examinations. The histology of most specimens approaches that of open biopsy

The VACORA™ Breast Biopsy System produces a large core of breast tissue for the pathologic examination. Clinicians familiar with pathologists know that pathologists prefer a larger sample. Why? All things being equal, a larger piece of tissue is more likely to include the lesion in question as opposed to missing it altogether. Larger samples include more of the lesion, uninvolved surrounding tissue to compare with the lesion and a panoramic view of the lesion. Samples obtained in piecemeal fashion simply don’t compare. Let’s look at each of these benefits on a separate basis.

A larger specimen is more likely to be representative of the lesion. This makes intuitive sense and is supported by a variety of studies. Experts on breast needle core biopsies uniformly tout increasing sensitivities with increasing needle size. Sensitivities of 65% with 18 gauge needles, 92% with

---

<sup>1</sup>Wilmington Pathology Associates, P.A.

BRIAN SHIRO, MD<sup>1</sup>

16 gauge needles and 97% and higher with 14 and 11 gauge needles have been reported (The Pathologists' Meeting, College of American Pathologists September 2003, Breast Pathology: Greater Issues and Smaller Specimens.) Sensitivity, the ability to detect the lesion and avoid a false negative diagnosis, increases with the size of needle core biopsy.

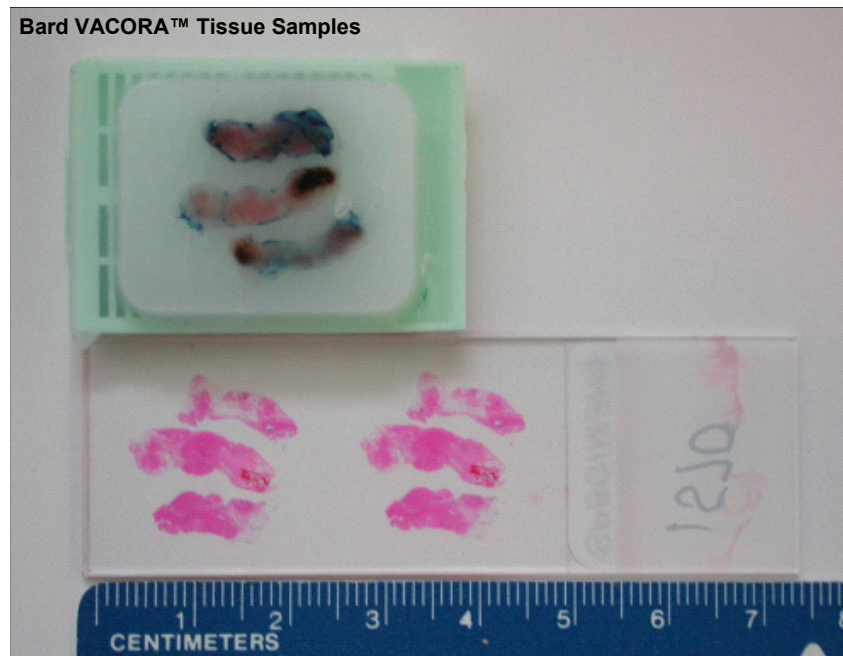
The avoidance of a false negative result is perhaps the most important aspect of breast needle core biopsy. This is true from a purely clinical sense since the sooner the diagnosis is made, the quicker treatment can begin. It is also true that failure to diagnose breast cancer is one of the more frequent reasons for malpractice claims and one of the most expensive.

Once the lesion has been sampled and is on the histology slide, then the pathologist must interpret the microscopic section. Bigger is better here as well. Think of a jigsaw puzzle broken up randomly in hundreds of sections. Now think of the same puzzle in only five randomly placed pieces or even better, two pieces. Our brains intuitively try to make sense of what our eyes see and this is far easier with the larger, less numerous pieces. One would be hard pressed to find a pathologist who'd prefer specimens be sampled in piecemeal fashion than by one or two larger samples of the same lesion.

A larger sample allows the pathologist to more confidently diagnose benign, intermediate or malignant lesions (Figure 1). With larger samples, uninvolved breast tissue often can be seen around the lesion in question, providing a valuable background to compare to the abnormality. This is helpful in benign lesions such as epithelial hyperplasia, atypical hyperplasia (lobular and ductal), as well as with well-differentiated carcinomas. When a diagnosis of malignancy has been made, a larger sample has still more benefits.

The histologic diagnosis of breast carcinoma is just the beginning of the pathologist's duties. There are a multitude of ancillary studies that must be done. At our own institution, we perform Estrogen and Progesterone immunohistochemical analysis on all ductal carcinoma in situ and all invasive breast carcinomas.

In addition, all invasive breast carcinomas are subjected to immunohistochemical analysis for Ki-67, a proliferative marker, and Her 2 Neu. A number of other markers are candidates for routine testing in the future. The benefit of a larger sample is obvious. The more representative tumor is present in a sample, the more likely that these ancillary tests will be successful at revealing the presence or absence of a tested antigen. Smaller samples tend to contain insufficient amount of tumor for accurate testing, necessitating repeat



**Fig 1.** BARD® Biopsy System VACORA™ System Tissue Samples

*Advantages of Using the VACORA™ Breast Biopsy System –A Pathologist’s Perspective*

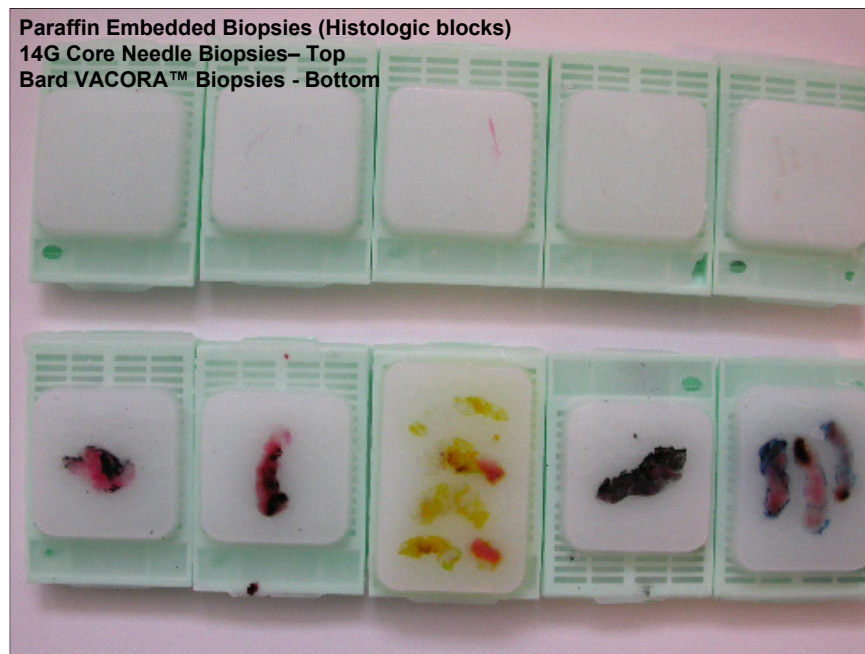biopsy (Figure 2). In my experience, the VACORA™ Breast Biopsy System provides a sample that includes all of the benefits described above. I first became aware of the VACORA™ Breast Biopsy System in the fall of 2003. One morning, I glanced at a tray of microscopic slides containing physician office based needle core biopsies of the breast. The microscopic sections of some of the cases contrasted sharply with others in the tray. The H and E stained tissue fragments were visibly larger, even to the naked eye (Figure 3). The contrast was just as dramatic under the microscope, perhaps more so. After viewing the entire tray, eight separate cases, it was clear that the larger samples originated from one office. I made a mental note of this finding and went about my business, pleasantly surprised at the ease of diagnosing the various benign and malignant lesions in the larger samples.

Two weeks later, I was discussing a case with a surgeon, when I remembered to ask him about the larger needle core biopsies of the breast that I had received. A big smile came across his face and he asked me what I thought. My gratitude was evident to say the least. I told him that the

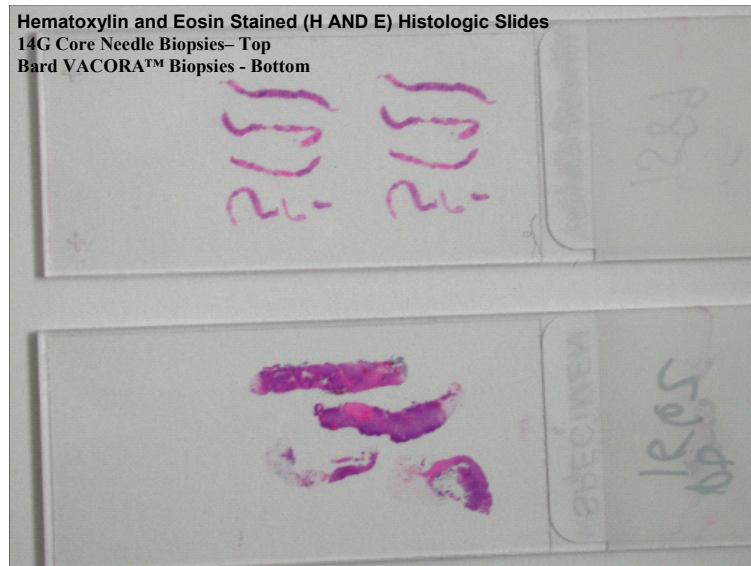
larger samples were a great service to pathologists and to patients.

“These new samples are just easier to read, and there is more tissue left for immunohistochemistry in the cancer cases.” The trend continued and I began to pay more attention to these larger samples, contrasting them to other CNB samples and with FNA. My conclusion is that the larger samples are superior for all the reasons given above. I have yet to see an inadequate sample from the VACORA™ Breast Biopsy System, yet we continue to see insufficient material with FNAs and occasionally with CNBs produced by alternative systems.

Our group includes two board certified cytopathologists. Both are experienced and extremely knowledgeable with regards to breast FNAs. They agreed with my assessment. My non-cytopathologist partners were equally enthusiastic. The VACORA™ Breast Biopsy System produces a superior sample that is easier to interpret and which allows for accurate ancillary testing of breast carcinoma cases. I recommend it without reservation for all ultrasound directed core needle biopsies of the breast.



**Fig 2.** Paraffin embedded biopsies (histologic blocks)  
14G Core Needle Biopsies – Top  
BARD® Biopsy System VACORA™ Breast Biopsy System Biopsies - Bottom



**Fig 3.** Hematoxylin & Eosin Stained (H & E) Histologic Slides  
 14G Core Needle Biopsies – Top  
 BARD® Biopsy System VACORA™ Breast Biopsy System Biopsies - Bottom

Please note that despite my enthusiasm, I would be remiss not to mention cautionary notes on core needle biopsy of the breast. First and foremost, whatever sampling device is used, accurate diagnosis is heavily dependent on the individual physicians involved. Several lesions diagnosed with 14G CNB require follow up by open biopsy. These include, but are not limited to, atypical lobular hyperplasia (ALH), lobular carcinoma in situ (LCIS), atypical ductal hyperplasia (ADH), papillary lesions, phyllodes tumor versus fibroadenoma and mucocoele-like lesion. The imaging and pathologic results must be correlated or be followed by repeat CNB or open biopsy. If done for microcalcification then calcification must be found on the slides or after X-ray of the histologic paraffin blocks. Done properly, Bard® Biopsy System’s VACORA™ Breast Biopsy System offers a core needle biopsy that is superior in a number of aspects. It saves time and is cost effective. Most importantly, the system produces a large representative sample which helps to ensure a rapid, accurate diagnosis.

## REFERENCES

- Pisano ED, Fajardo LL, Tsimakas J, et al. Rate of insufficient samples for fine needle aspiration for nonpalpable breast lesions in a multicenter clinical trial. The Radiologic Diagnostic Oncology Group 5 Study. *Cancer* 82:679-688, 1998.
- Kaye MD, Vicinanza-Adami CA, Sullivan ML. Mammographic findings after stereotaxic biopsy of the breast performed with large-core needles. *Radiology*, 192(3): 793-795, 1994.
- The Pathologists' Meeting, College of American Pathologists, Breast Pathology: Greater Issues and Smaller Specimens, September 2003.
- Barclay L. American Roentgen Ray Society Annual Meeting Abstracts 032, 036 Presented May 5, 2003.
- Colorado Society of Pathology Summer Meeting, Needle Biopsy of the Breast, July 2004.
- Parker SH, Burbank F, Jackman RJ, et al. Percutaneous large core breast biopsy: Multi-institutional study. *Radiology* 193: 359-364, 1994.
- Sneige N. A comparison of fine needle aspiration, core biopsy and needle localization biopsy techniques in mammographically detectable non palpable breast lesions. *Pathol Case Review* 1: 6-11, 1996.
- Liberman L. Advanced Breast Biopsy Instrumentation (ABBI): analysis of published experience. *AJR* 172: 1413-1416, 1999.